



## REPORT

EMI Inc.  
2030 W. First St., Suite E  
Fort Myers, Florida 33901  
admin@emiinterp.com

Ronald I Blum  
MD FACOEM. FAAFP.

Matt Sullivan  
MD

Ann Stanger  
MD

Miriam Devlin  
MD

Bina Santram  
MD

Darren Wright  
MD

Mario Soteriou  
MD

Marcel Meelis  
MD

D. Andrianopoulos  
MD

Brian Tyler  
MD

Bryan Cotton  
MD

Casper Lacle  
MD

Israel Posner  
MD

John Ward  
MD

Karen Pendleton  
MD

Shannon Tyler  
MD

**Patient:** XXXXX XXXXXXXX  
**Date of Birth:** XX/XX/XXXX  
**Patient ID:** XXXXXX  
**Referring Practitioner:** XXXXXX

**Reported By:** Bryan Cotton MD

**Scan Date:** 10/4/2011  
**Report Ref:** XXXXXX  
**Report Type:** Full Body  
**Thermographer:** anette  
abrahamsen

**All normal protocols were observed**

**HISTORY AND SUBJECTIVE COMPLAINTS:**

tension headache . osteoarthritis in the neck and spine (spondylosis)  
stabbig pain in the back of both thighs when client is lying down

**THERMOGRAPHIC INTERPRETATION:**

**HEAD AND NECK:**

Patchy hyperthermia scattered over the maxilla and mandible suggest dental or periodontal inflammation. There is inflammation over both carotid arteries which suggests elevated CRP levels or plaque formation. There are no thermal findings to indicate sinus, TMJ or thyroid dysfunction.

**CHEST:**

Myofascial hyperthermia scattered over the anterior chest which is nonspecific.

**BACK:**

There is myofascial hyperthermia over both trapezius and rhomboid areas which suggest inflammation and may contribute to the neck pain. Inflammation is present of the lumbosacral spine which may indicate degenerative changes of the joints and discs and contribute to his pain.

**ABDOMEN:**

The linear areas of muscular hyperthermia over the left side of the abdomen are nonspecific. There are no thermal patterns to suggest visceral dysfunction.

**UPPER EXTREMITIES:**

There is inflammation around both shoulders, both elbows and both wrists which may indicate arthritis.

**LOWER EXTREMITIES:**

There is extensive vascular hyperthermia over the needle aspect of the left thigh, left knee and around the left calf which suggests extensive varicosities. Inflammation is present over the anterior aspect of both knees which suggests significant arthritis and may contribute to his pain

**DISCUSSION:**

Clinical evaluation of the carotid arteries is recommended.

**FOLLOW-UP:**

Suggest clinical correlation of thermal findings with patient's history and symptoms.

**PROCEDURE:**

This patient was examined with digital infrared thermal imaging to determine if asymmetrical thermal findings indicate abnormal physiology.

Thermography is a physiologic test which demonstrates thermal patterns in skin temperature that may be normal or which may indicate pain, injury, disease or other abnormality. If abnormal heat patterns are identified relating to a specific

region of interest or function, clinical correlation and further investigation may be necessary to assist your health care provider in diagnosis and treatment.

Thermal imaging is an adjunctive test which contributes to the process of differential diagnosis, and is not independently diagnostic of pathology.

**PROTOCOLS:**

The thermographer certifies that this exam was conducted under standard and clinically acceptable protocols.

**PATIENT HISTORY:**

The interpretation represents objective descriptions of thermal patterns. Clinical significance of such patterns is interpreted in relation to and limited by the patient data and history provided.

**REPORTING:**

Results are reported by certified thermologists. Results are determined by studying the varying patterns and temperature differentials as recorded in the thermal images.

**NORMAL FINDINGS:**

Normal findings are diffuse thermal patterns with good symmetry between similar regions on both sides of the body. Comparative imaging may identify specific asymmetries that have remained stable and unchanged over time and therefore regarded as normal.

**ABNORMAL FINDINGS:**

Abnormal findings may be localized areas of hyperthermia or hypothermia, or thermal asymmetry between similar regions on both sides of the body with temperature differentials of more than 1° C. There may be vascular patterns that suggest pathology. Comparative imaging may identify specific changes or new asymmetries that warrant further investigation.

**COLD STRESS:**

If a cold stress test was performed to evaluate the sympathetic response to a suspicious thermal pattern, the results are interpreted as follows:

**Positive:**

A positive result will demonstrate no thermal change to the suspicious pattern and concurrent normal physiologic responses in other areas of the body, particularly the contralateral parallel region.

**Negative:**

A negative result will demonstrate normal physiologic thermal responses in all areas of the body including the suspicious pattern.

Results of cold stress testing should not be considered conclusive or diagnostic.

The referring health care provider should contact the EMI administrator with any questions relating to this interpretive report.

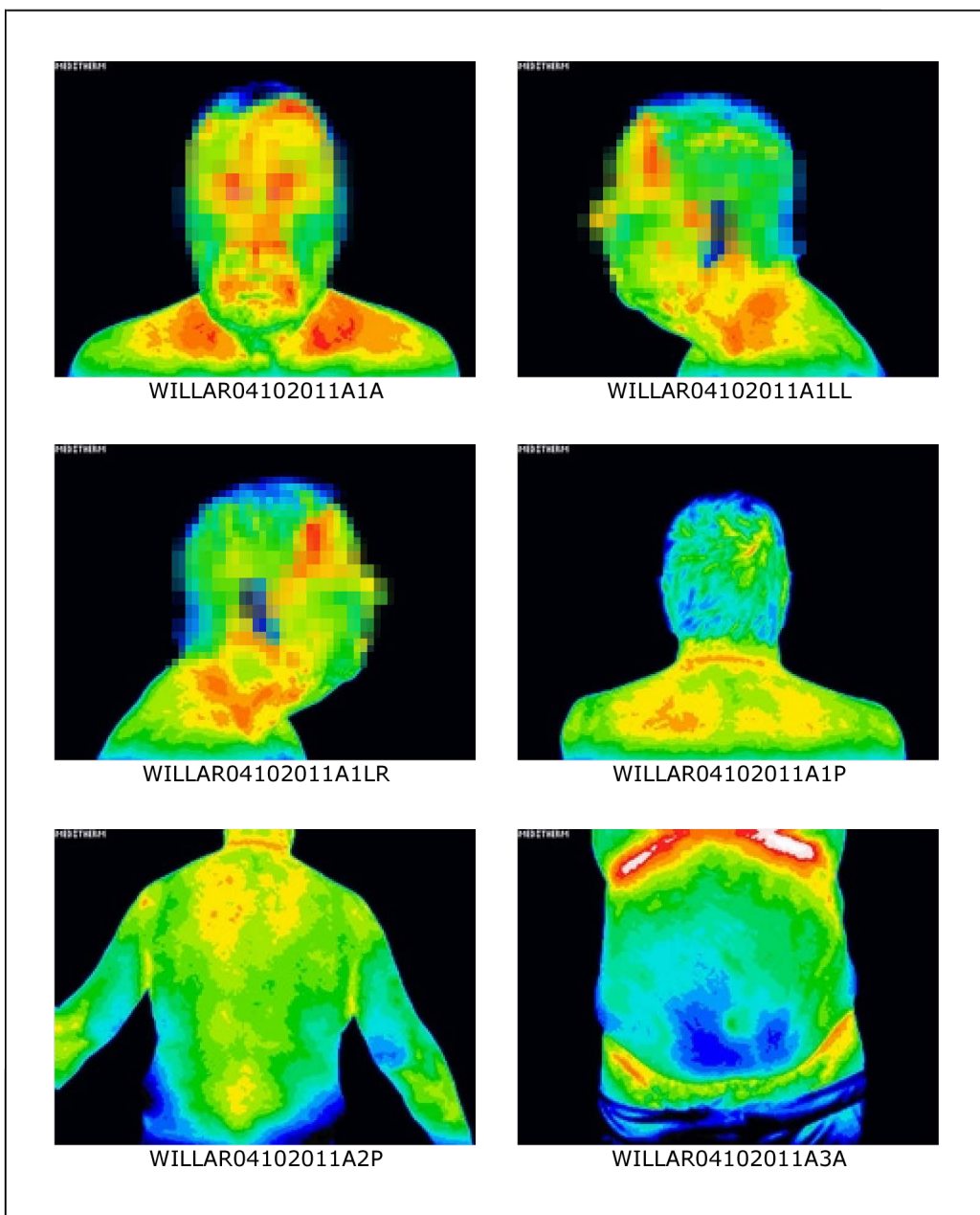
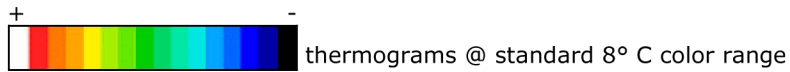
This Report is intended for use by trained health providers to assist in evaluation, diagnosis, and treatment. It is not intended for use by individuals for self-evaluation or self-diagnosis. This Report does not provide a diagnosis of illness, disease or other condition.



# THERMOGRAMS

**Patient:** XXXXX XXXXXXXX  
**Date of Birth:** XX/XX/XXXX  
**Patient ID:** XXXXXX  
**Referring Practitioner:** XXXXXX

**Scan Date:** 10/4/2011  
**Report Ref:** XXXXXX  
**Report Type:** Full Body  
**Thermographer:** anette abrahamsen



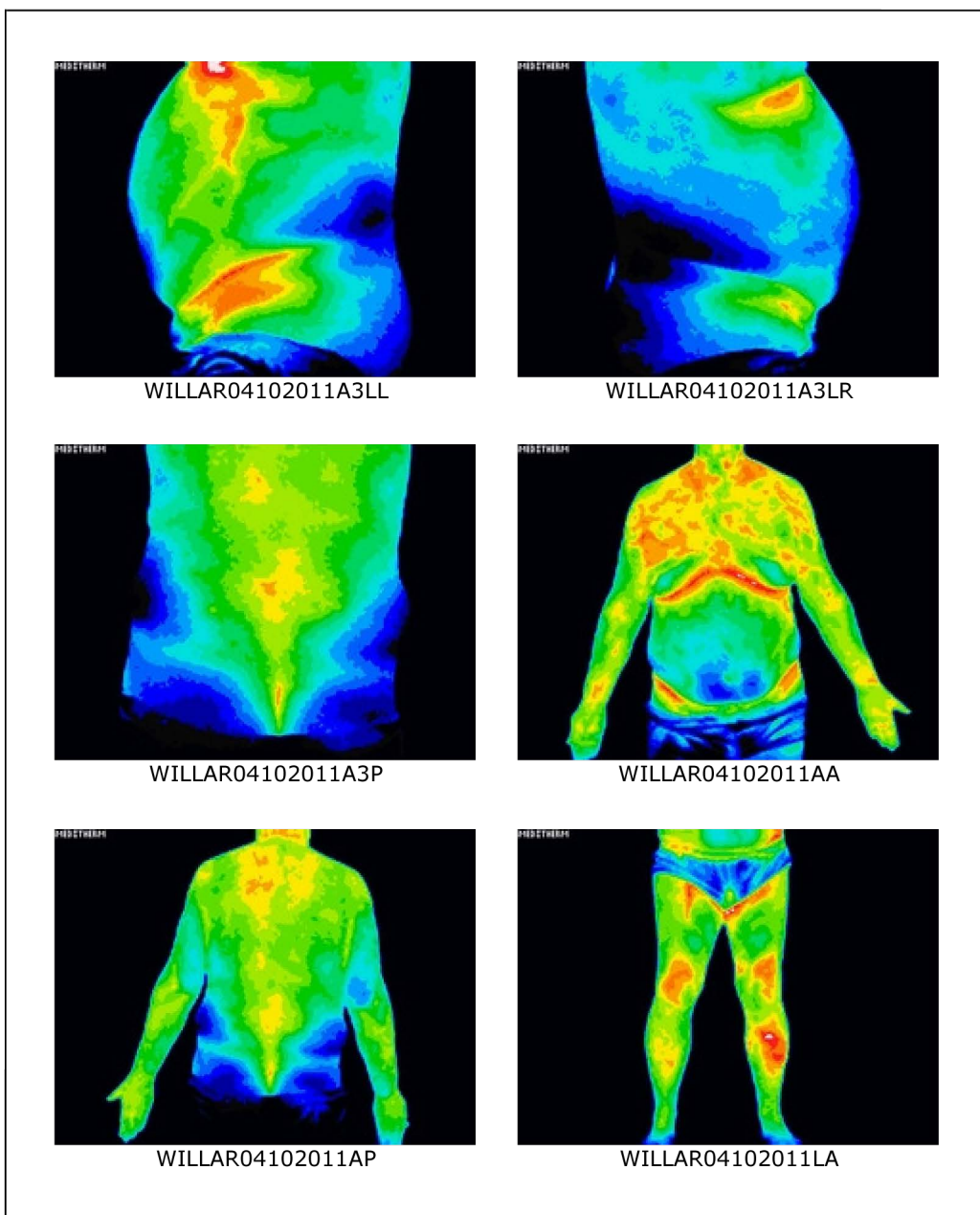
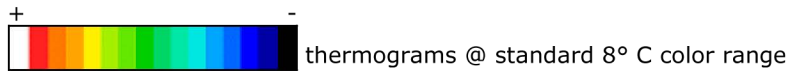
Copyright © 2001 - 2007 Electronic Medical Interpretation Inc. All rights reserved.



# THERMOGRAMS

**Patient:** XXXXX XXXXXXXX  
**Date of Birth:** XX/XX/XXXX  
**Patient ID:** XXXXXX  
**Referring Practitioner:** XXXXXX

**Scan Date:** 10/4/2011  
**Report Ref:** XXXXXX  
**Report Type:** Full Body  
**Thermographer:** anette abrahamsen



Copyright © 2001 - 2007 Electronic Medical Interpretation Inc. All rights reserved.




Electronic Medical Interpretation

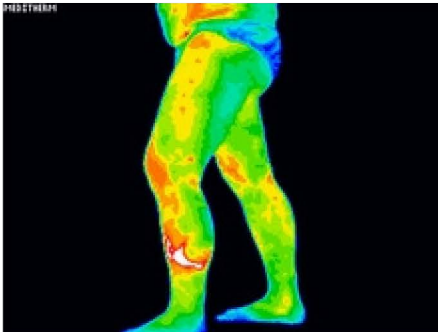
## THERMOGRAMS

**Patient:** XXXXX XXXXXXXX  
**Date of Birth:** XX/XX/XXXX  
**Patient ID:** XXXXXX  
**Referring Practitioner:** XXXXXX

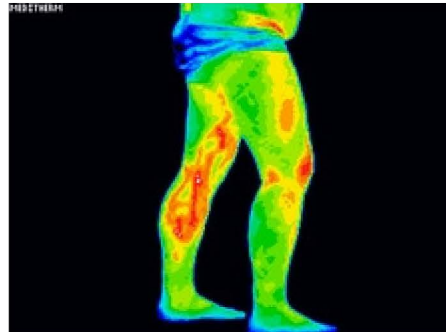
**Scan Date:** 10/4/2011  
**Report Ref:** XXXXXX  
**Report Type:** Full Body  
**Thermographer:** anette  
abrahamsen



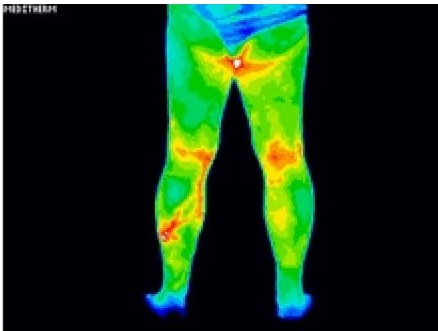
thermograms @ standard 8° C color range



WILLAR04102011LLL



WILLAR04102011LLR



WILLAR04102011LP